

STATdx

# KAPSAM

- 4300'den fazla teşhis bilgisi;
- 200.000 yüksek kalitede görüntüleme örneği;
- Uzmanlar tarafından oluşturulmuş 1,300 ayırıcı tanı listesi, 200.000'den fazla yüksek kalitede imaj;
- 20.000'den fazla kolayca sınıflandırılabilir hasta vaka örneği;
- 300 geniş kapsamlı anatomi modülü;
- 195 prosedür ile
- Kanser derecelendirme referans tablo ve hesaplayıcıları içermektedir.
- Tüm konular uzmanlar tarafından yazılmakta ve uzmanlar tarafından seçilmiş dergi ve kitap referansları tarafından desteklenmektedir.

# KAPSAM

- X-ray, CT, MR ve ultrason görüntüleri ve canlı renklere grafiklerin yer aldığı imaj görüntüleri içinde arama yapılabilir.
- Compare Anywhere özelliği ile 3'e kadar teşhis görüntüsü yan yana konarak karşılaştırma yapılabilir.
- En nadir hastalık örneklerini dahi araştırma olanağı sağlar.
- RADSearch ile en son dergi makaleleri takip edilebilir.



# Gazi Üniversitesi Merkez Kütüphanesi



[Ana Sayfa](#) [Kütüphane Hakkında](#) [Kullanım Koşulları](#) [Çalışma Saatleri](#) [Personel](#)

Katalog Tarama

Gazi Search

Anahtar Kelime

tez

Ara

## Elektronik Kaynaklar

[E-Kaynaklar Kullanım Kuralları](#)

[Elektronik Dergiler](#)

[Elektronik Kitaplar](#)

[Elektronik Makale](#)

[Elektronik Tezler](#)

[Veri Tabanları](#)

[INCITES](#)

## Hizmetler

[Referans Hizmetleri](#)

[Kütüphanelerarası İşbirliği](#)

[Atıf İndekslerde Gazi](#)

[Yeni Gelen Yayınlar](#)

## Formlar

[Kullanıcı Eğitimi İstek Formu](#)

[Yayın Sipariş Formu](#)










[Kütüphanelerarası İşbirliği Formları](#)

[Veri Tabanları Değerlendirme Formu](#)

[Deneme Veri Tabanları Değerlendirme Formu](#)

[Duyurular](#)

«Veri Tabanları»  
bağlantısına tıklayınız.

Social Sciences Index Retrospective: 1907 & 1983 (EBSCO)	
SPORTDiscus with Full Text (EBSCO)	
Springer LINK	
Springer E-Kitaplar	
STATdx	
Taylor & Francis	
Teacher Reference Center (EBSCO)	
Thieme	
Total Materia	
TSE - TÜRK STANDARTLARI Sadece Kütüphanemizden kullanılabilir.	
Turnitin (Tez İntihal Engelleme Programı) Tez danışmanlarının sisteme giriş yapabilmesi için erişim tanımlamaları ilgili Enstitüler tarafından yapılacaktır. Erişim	

«STATdx»  
bağlantısına tıklayınız.



## Primary Categories

6880 topics

Recently Viewed

Recently Updated

<b>Brain</b> 617 topics 	<b>Breast</b> 245 topics 	<b>Cardiac</b> 168 topics 	<b>Chest</b> 818 topics 
<b>Gastrointestinal</b> 459 topics 	<b>Genitourinary</b> 195 topics 	<b>Gynecology</b> 155 topics 	<b>Head and Neck</b> 765 topics 
<b>Interventional Radiology</b> 155 topics 	<b>Musculoskeletal</b> 867 topics 	<b>Nuclear Medicine</b> 150 topics 	<b>Obstetrics</b> 335 topics  Fetal HR = 75 bpm
<b>Pediatrics</b> 857 topics 	<b>Spine</b> 459 topics 	<b>Ultrasound</b> 670 topics 	<b>Vasculature</b> 60 topics 

Yesterday

[Sjögren Syndrome](#)

Chest > Diagnosis > Connective ...

Yesterday

[Ulcerative Colitis](#)

Gastrointestinal > Diagnosis > C...

Yesterday

[Crohn Disease](#)

Gastrointestinal > Diagnosis > S...

Yesterday

[Iron Overload Syndromes](#)

Cardiac > Diagnosis > Heart Fail...

Yesterday

[Hemochromatosis](#)

Musculoskeletal > Diagnosis > N...

12/09/19

[Hyperechoic Kidney](#)

Genitourinary > Differential Diagn...

12/09/19

[Multiple Pulmonary Nodu...](#)

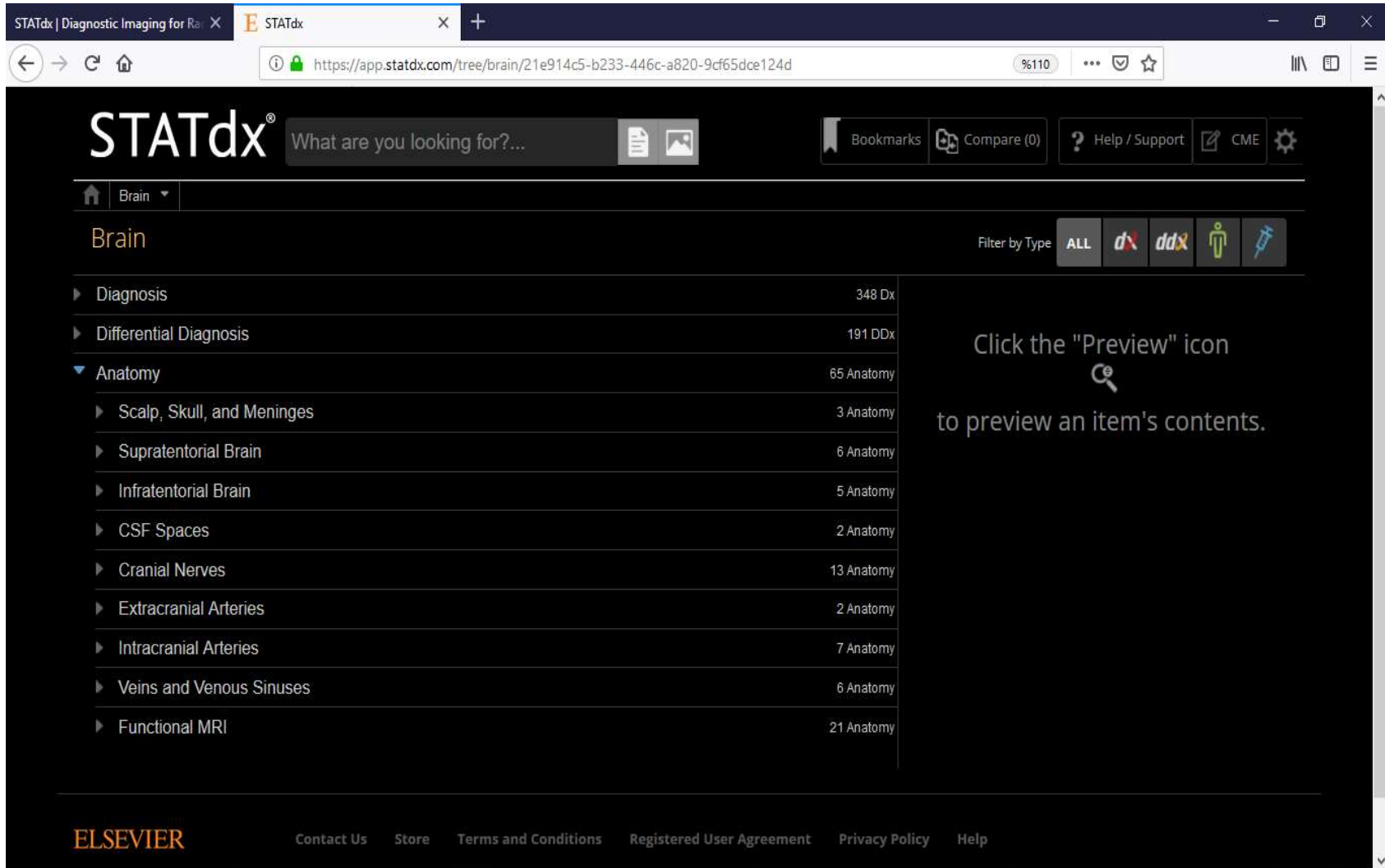
Pediatrics > Differential Diagnosi...

12/09/19

[Multiple Pulmonary Nodu...](#)

Chest > Differential Diagnosis > ...

# Kategoriler içinde İlgili Anatomi Modülleri



The screenshot shows the STATdx website interface. The browser address bar displays the URL: <https://app.statdx.com/tree/brain/21e914c5-b233-446c-a820-9cf65dce124d>. The main navigation bar includes the STATdx logo, a search bar with the placeholder text "What are you looking for?...", and utility buttons for Bookmarks, Compare (0), Help / Support, and CME. The current category is "Brain". Below the category name, there is a "Filter by Type" section with buttons for ALL, dx, ddx, and a person icon. The main content area displays a list of modules under the "Brain" category:

Module	Count
Diagnosis	348 Dx
Differential Diagnosis	191 DDx
Anatomy	65 Anatomy
Scalp, Skull, and Meninges	3 Anatomy
Supratentorial Brain	6 Anatomy
Infratentorial Brain	5 Anatomy
CSF Spaces	2 Anatomy
Cranial Nerves	13 Anatomy
Extracranial Arteries	2 Anatomy
Intracranial Arteries	7 Anatomy
Veins and Venous Sinuses	6 Anatomy
Functional MRI	21 Anatomy

A callout box on the right side of the screen contains the text: "Click the 'Preview' icon to preview an item's contents." with a magnifying glass icon.

The footer of the page features the ELSEVIER logo and several links: Contact Us, Store, Terms and Conditions, Registered User Agreement, Privacy Policy, and Help.

# Anatomi Alt Başlıkları

The screenshot shows the STATdx website interface. The browser address bar displays the URL: <https://app.statdx.com/treenode/cranial-nerves/70654748-d3b7-4293-8de7-56995c1d0706>. The page title is "Cranial Nerves". The navigation menu includes "Brain", "Anatomy", and "Cranial Nerves". The main content area lists various cranial nerves with their respective image counts and update dates. A "Filter by Type" section is visible, with options for "ALL", "dx", "ddx", and "i". A callout box on the right side of the page instructs the user to click the "Preview" icon to view the contents of an item.

Cranial Nerve	Author(s)	Image Count	Update Date
<b>Cranial Nerves Overview</b>	by H. Ric Harnsberger, MD; Philip R. Chapman, MD	30 images	Updated 04/16/18
<b>CNI (Olfactory Nerve)</b>	by Aparna Singhal, MD; H. Ric Harnsberger, MD	8 images	Updated 07/30/18
<b>CNII (Optic Nerve)</b>	by Philip R. Chapman, MD; H. Ric Harnsberger, MD	19 images	Updated 05/23/18
<b>CNIII (Oculomotor Nerve)</b>	by Philip R. Chapman, MD; H. Ric Harnsberger, MD	20 images	Updated 07/26/18
<b>CNIV (Trochlear Nerve)</b>	by Philip R. Chapman, MD; H. Ric Harnsberger, MD	8 images	Updated 07/26/18
<b>CNV (Trigeminal Nerve)</b>	by Surjith Vattoth, MD, FRCR	30 images	Updated 05/10/18
<b>CNVI (Abducens Nerve)</b>	by Philip R. Chapman, MD; H. Ric Harnsberger, MD	8 images	Updated 07/26/18
<b>CNVII (Facial Nerve)</b>	by Philip R. Chapman, MD; H. Ric Harnsberger, MD	21 images	Updated 07/03/18
<b>CNVIII (Vestibulocochlear Nerve)</b>	by Philip R. Chapman, MD	15 images	Updated 07/03/18

Click the "Preview" icon to preview an item's contents.

# Aynı Düzende Konu Başlığı Sıralaması

STATdx | Diagnostic Imaging for Ra X STATdx

https://app.statdx.com/document/cnii-optic-nerve/88db2825-3976-4a3b-917c-9366d3e6b57f

## STATdx®

What are you looking for?...

Bookmarks Compare (0) Help / Support CME

Brain Anatomy Cranial Nerves CNII (Optic Nerve)

### CNII (Optic Nerve)

Philip R. Chapman, MD; H. Ric Harnsberger, MD

Claim CME Bookmark Print

#### TERMINOLOGY

Abbreviations

- Optic nerve: CNII

Synonyms

- 2nd cranial nerve

Definitions

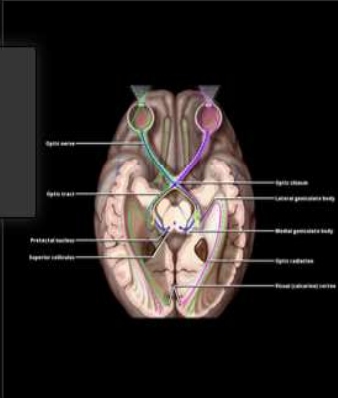
- CNII: Nerve of sight
- Visual pathway consists of optic nerve, optic chiasm, and retrochiasm structures

#### IMAGING ANATOMY

Overview

- Optic nerve **not** true cranial nerve but rather **extension of brain**
  - Represents collection of retinal ganglion cell axons
  - Myelinated by **oligodendrocytes** not by Schwann cells as with true cranial nerves
  - Enclosed by meninges
  - Throughout its course to visual cortex, nerve fibers are arranged in **retinotopic order**
- Optic nerve has 4 segments
  - Intraocular, intraorbital, intracanalicular, and intracranial
- Partial decussation CNII fibers within optic chiasm


TERMINOLOGY  
IMAGING ANATOMY  
ANATOMY IMAGING ISSUES  
CLINICAL IMPLICATIONS



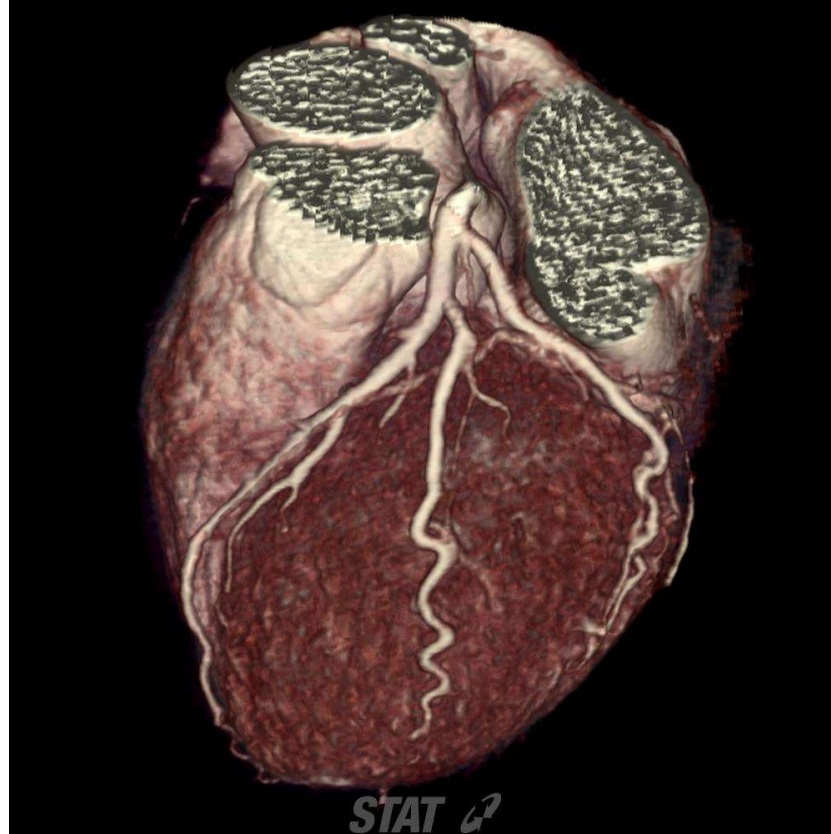
View Full Screen Image

Axial graphic through the visual pathway shows medial retinal fibers crossing in the optic chiasm so that fibers from left 1/2 of both retinas course in left optic tract, and

Graphics 4



# İmajları Doğrudan PowerPoint Sunusuna Aktarma



3D volume-rendered image shows the left coronary arteries.

# Teşhis Sayfalarında, İlgili Anatomi Konuları

STATdx | Diagnostic Imaging for Ra... x STATdx x +

https://app.statdx.com/document/steatosis-fatty-liver/8cd1a5c5-97b4-4202-9e1f-cf4727753283

## STATdx®

What are you looking for?...

Bookmarks Compare (0) Help / Support CME

Gastrointestinal Diagnosis Liver Inflammation Steatosis and Steatohe...

### Steatosis and Steatohepatitis

Michael P. Federle, MD, FACR

Claim CME Compare Bookmark Print

#### KEY FACTS

0 Terminology

- Steatosis is metabolic complication of a variety of toxic, ischemic, and infectious insults to liver
- Characterized by accumulation of increasing amounts of triglycerides within hepatocytes

25


2 Imaging

19 Anatomy

- Diffuse (more common) or focal fatty infiltration
  - Often lobar, segmental, or wedge shaped
  - Along hepatic vessels, ligaments, and fissures
  - Presence of normal vessels coursing through "lesion" (fatty infiltration)
- NECT: Liver attenuation < spleen
- US: ↑ echogenicity, ↑ attenuation of sound beam
- Best imaging clue
  - Decreased signal intensity of liver on T1 opposed-phase GRE images
- Nonalcoholic steatohepatitis (NASH) looks similar to simple steatosis and alcoholic steatohepatitis

#### Top Differential Diagnoses

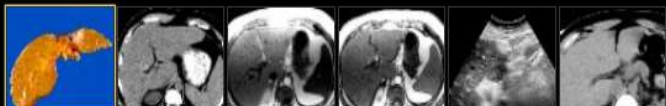
- Lymphoma or metastases
  - Diffuse or multifocal lesions can be seen with steatosis or tumor
- Hepatitis
  - Viral or other toxic etiologies



View Full Screen Image

Cut section of an explanted liver shows a yellowish, greasy, pale appearance due to steatosis. Steatohepatitis can lead to progressive and irreversible liver failure.

Selected Images 16



**Teşekkürler...**